

Chapter 46: Polylactic acid fillers

Kenneth Beer

Palm Beach Esthetic, West Palm Beach, FL, USA

BASIC CONCEPTS

- Polylactic acid fillers (PLLA) is a volume stimulator rather than a direct volume replacement.
- PLLA is best suited for areas that are concave.
- PLLA results are dependent on techniques such as dilution and injection.
- Complications from PLLA are different from those from fillers and include subcutaneous papule formation.
- PLLA results (both good and bad) may last for years.

Introduction

1 Poly-L-lactic acid is the active ingredient found in Sculptra® (also known as New-Fill; Sanofi-Aventis, Paris, France). Each bottle of material also contains sodium carboxymethylcellulose (USP) and non-pyrogenic mannitol [1]. The sodium carboxymethylcellulose and mannitol act to stabilize the PLLA and have no biologic effect on the volume stimulation. The material comes as a freeze-dried powder that must be reconstituted with sterile water [2]. At the present time, Sculptra is the only product of its kind and as such is unique.

Although the amount of PLLA in a bottle of Sculptra is fixed at 367.5 mg, the methods of reconstitution are variable. The ability to add different amounts of water and/or lidocaine is one opportunity for physicians to vary the use of this material and may contribute to varying reports of success and complications. Initial reports of product use in Europe utilized dilutions of 3 mL per bottle [3]. The duration of reconstitution for these early studies was 4 hours. The package insert for the product recommends a reconstitution time of 4 hours; however, many PLLA injectors advocate longer periods, with some recommending that water imbibe for at least 24 hours with longer periods of up to 3 weeks also touted. At the present time, there is no uniform consensus nor clinical trial to suggest what is the optimal dilution or reconstitution time. This author recommends using at least 4 mL water for at least 24 hours, with longer periods of time being preferable.

In addition to the 4 mL water, various anesthetic agents are added to the mixture. The anesthetic added to the

product varies depending on injector preferences and experiences. Among the alternatives used, 1% lidocaine with 1:100k epinephrine added is perhaps the most frequently used. Lidocaine without epinephrine (1%) and 2% lidocaine are also used.

Volumes of anesthetic added to the reconstituted material also vary based on the location of each injection and the experience of the injector. At the present time, many skilled injectors utilize 4 mL water for at least 24 hours and immediately before injection add 3–4 mL of 1% lidocaine with epinephrine. When injecting areas such as the back of the hands or the tear trough under the eye, this dilution may require additional water and the total reconstitution volume for these areas is 9 mL for many injectors. For the 9-mL dilution, the author uses 4 mL water and 5 mL 1% lidocaine with 1:100 000 epinephrine.

Once reconstituted, the bottle should be signed and dated and the material should be stored in a refrigerator. Before injection, it should be left out so that it can warm to room temperature. Whether or not gently heating it to body temperature before injecting to improve outcomes is another area of controversy. At the present time, it seems reasonable to inject material that is at room or body temperature but not to heat the product beyond these temperatures.

Advantages and disadvantages

PLLA has many unique properties and strengths and weaknesses. Among the strengths of the product are its long-lasting nature, ability to correct large volume losses, and ease of injection. Weaknesses of the product include the formation of subcutaneous papules, multiple injection visits, expense, and, most importantly, there is no way to predict the degree of improvement that will result from any given injection. This latter point means that unlike the hyalurons,

collagens, or calcium hydroxylapatite, there is no way for a physician to correct a given area with a 1:1 defect to product replacement ratio. Instead, the injector must wait to see the extent to which new collagen will form.

One of the advantages of this product is its ability to produce collagen, providing a correction that lasts for more than 1 year [4]. Unlike any of the fillers, except for the permanent ones such as silicone or Artefill, once PLLA has attained a volume correction it will last for a prolonged amount of time. In addition, when the correction is diminishing, it can be enhanced with a touch up injection. Despite the initial high cost of injection, the degree and duration of the PLLA correction makes it cost effective. Volume replacement for moderate lipoatrophy costs \$3000–4000. When compared with the cost of other fillers for the same time interval, PLLA correction is reasonably priced.

PLLA is technically easy to inject. In fact, the difficulty associated with this product lies more with poor patient selection, inappropriate and inadequate volume reconstitution. The very nature of the product as it is injected (it is a suspension rather than a solution or gel) means that even with the best technique, particles of PLLA will migrate following injection. In addition, density differences both in the syringe and in the patient as the PLLA particles settle provide non-homogeneous product dispersion even with the best technique.

Standard injection techniques

Beginners should not have technical problems injecting this product as long as they select the right patients and locations to treat. The most common problem encountered by novice injectors is clogging of material in the needle, resulting in sporadic injections of product under high pressure and placement of the product at the wrong plane.

Rapid injection is the best technique for injecting PLLA. This avoids needle clogs producing high pressure injections and areas of high and low concentration product placement. Injection needles should be either 25 or 26 gauge and 0.5 inch in length. Smaller bore and longer needles may result in difficulty extruding the product into the tissue.

Injections of PLLA require deep product placement. Thus, the needle should be at the level of the deep dermis or dermal–subcutaneous junction. Superficial placement will increase the probability of visible papule formation. Various methods of injecting including serial puncture, linear threading, and fanning have been described and espoused. Standard injection techniques should try to include aspects of each because the goal of the injection is to obtain a homogeneous distribution of product at the plane where it will do the most good. Which technique predominates for a given individual depends on the area being injected and the amount of product being placed. Following any technique, it is essential to massage the product vigorously to distribute it. When massaging, deep pressure adequate to move product from discrete pearls into a contiguous plane is required.

The most frequently injected areas are the cheeks, jawline, and temples. For the cheeks, it is helpful to inject half a bottle (3.5 mL) per session into each cheek. Each injection should be accomplished such that approximately 0.05 mL is inserted and the space between injections is about 0.5 cm. Serial puncture and fanning may be combined to produce a spoke-like network of injections (Figure 46.1). Typical injection schedules for the cheeks include three injections spaced at least 1 month apart. Patients with severe lipoatrophy may require more injections and it is acceptable to continue injections until full volume restoration is accomplished. However, it is not advisable to decrease the time interval between sessions.

Correction of jawline volume loss may be required following loss of subcutaneous tissue and bone resorption. PLLA

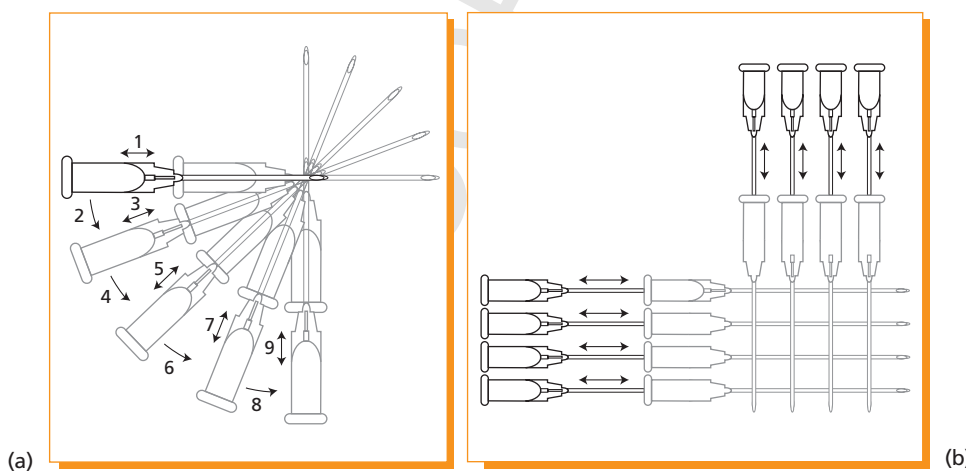


Figure 46.1 Serial puncture and fanning techniques. (a) Fan technique. (b) Cross-hatching technique.

injections may be performed to stimulate collagen in this area with outstanding results. Standard injection techniques for this area are serial puncture and fanning. Needle insertion for this location should be at the level of the deep tissue (subcutaneous or just above the periosteum). As with other locations, deep massage is necessary to move the product into a homogeneous plane.

Needle orientation for the jawline is typically at 45° to the skin. Moderate volume loss may be treated with 2–3 mL of the 7-mL dilution of PLLA and can be completed in three visits for many patients. Severe volume loss may be treated with four or more injection sessions.

Temporal wasting is one of the hallmarks of facial aging. Although other products may be used to treat this, PLLA is exceptionally well suited for this application. Injections in this location have several potential pitfalls that need to be avoided.

The plethora of blood vessels in this area provides one potential pitfall for injection of any product and the particulate nature of PLLA is no exception. When injecting the temples with PLLA, it is important to aspirate prior to inserting product. Needle placement should be deep and at the level just superficial to the periosteum. Placement at this level will help avoid formation of visible subcutaneous papules.

Average injection volume per side is 2–3.5 mL using the 7-mL volume dilution. The technique for injecting PLLA in this area is predominantly the fanning method but serial puncture is also used.

Advanced techniques

Perhaps the most important consideration when performing advanced techniques is to change the dilution and volume to accommodate the different areas being treated. Advanced techniques for injecting PLLA may be utilized to treat areas such as the tear troughs and the dorsum of the hands. When treating these areas, it is worthwhile to dilute each bottle with 9 mL of total volume rather than with 7 mL.

Tear troughs are one of the most difficult areas to treat with any injection and PLLA is no exception. There are some additional considerations for this material that warrant special consideration. Unlike standard techniques, this area is one that should be treated only by injectors with advanced skills and experience. Whereas half of the bottle is used for each side of each location treated with simple techniques, it is recommended that about 1–2 mL of the 9-mL diluted product be used for each side of the tear trough. When treating the tear trough, using the non-dominant hand to palpate the margin of the infraorbital rim will help to protect the eye and make certain that the injections remain outside of the globe. As with injections into the temple, aspiration of the syringe is essential prior to the injection. The multitude

of vessels in this area require caution when injecting and although blindness has not yet been reported with PLLA injections, it is a theoretical possibility that needs to be remembered when injecting.

Placement of the needle for treatments of the tear trough are at the level immediately superficial to the periosteal plane. Orientation of the needle is either perpendicular to the skin or at 45° to the skin and directed medially. When injecting the tear troughs, never point the needle towards the globe as this may result in inadvertent punctures.

Each injection should place a small amount of material (about 0.05 mL). Injections should be about 3–5 mm apart. Following placement, each should be massaged to avoid discrete nodule formation. Despite perfect technique, injections of PLLA may result in the delayed formation of nodules and patients should be aware of this possibility prior to treatment [5].

Dorsal hand lipoatrophy and photoaging are hallmarks of aging that are frequently left untreated because of the lack of effective modalities. The use of PLLA for this location is a technique utilized by advanced injectors with very good results. As with injections of the tear trough, the dorsal hands are covered with skin that is typically thin and translucent. Thus, dilution of each bottle of Sculptra with 9 mL liquid is appropriate.

Longer needles such as 1 inch may be used to treat the dorsal hands. The needle may be inserted proximally and advanced parallel to the tendons and material inserted as the needle is withdrawn. Photoaged hands typically have prominent veins and care must be taken to avoid injections into these structures. Each hand will require about half a bottle per treatment session and approximately 9–10 injection sites to cover the entire hand.

Complications

The most common complications related to injections of PLLA are injection site related [2]. These include bruising, erythema, and site-related discomfort. More serious complications include nodule formation known as subcutaneous papules. These nodules are typically foreign body type granulomas mixed in with collagen matrix [6]. The subcutaneous nodules may be treated with injections of intralesional cortisone and it is reasonable to begin treatments with 2.5–5 mg/mL triamcinolone acetonide. Injections may be performed on a monthly basis until the nodule resolves. In the event that the nodule does not resolve after multiple injections it is possible to remove it surgically using a small incision.

More serious complications are possible with injections of PLLA (or any material) and these include necrosis of the skin. This could result from intravascular injection of PLLA and it is wise to aspirate prior to injections near major

vascular structures. Inadvertent excursions of the needle into the globe may also occur with PLLA injections (or those of any product) when the periorbital area or tear troughs are injected. The injector should take care to use the non-dominant hand to palpate the infraorbital ridge and to orient the needle away from the eye so that if the patient makes a sudden movement, the needle will not jab them.

PLLA compared with other fillers

With the advent of porcine collagen, calcium hydroxylapatite, and new forms of hyaluronic acid, one question asked by some physicians is when PLLA should be used and what patients should be treated with it. PLLA is not a direct volume replacement material and instead causes the body to replace collagen. Thus, it is not a substitute product for the various fillers. Many patients that need discrete line filling will have volume loss associated that can be treated with PLLA. Patients that only require volume replacement of the malar, temporal, or jaw areas may also obtain optimal results with PLLA.

Deciding where PLLA fits into one's practice is as much a patient selection issue as a technical one. Patients who have the temperament and budget to accept a gradual volume replacement should be treated with this product. Patients demanding a single visit correction should not. In addition, because there is no way to anticipate fully how any given individual will manufacture collagen, patients who will not tolerate a treatment program should be avoided.

Conclusions

PLLA is a unique molecule capable of restoring significant amounts of subcutaneous volume for long periods of time. It causes the body to make collagen and other extracellular matrix proteins. Unlike other products used in cosmetic dermatology, PLLA cannot produce exactly predictable results and it requires multiple treatment sessions to achieve its planned correction. Used judiciously, it can correct deficits that would otherwise be difficult to correct. PLLA has some unique complications that should be understood before it is used and patient selection is perhaps more important with this product than any other. However, its unique properties offer cosmetic dermatologists unique opportunities and this product should be embraced by injectors who understand its strengths and weaknesses.

References

- 1 Beer K. (2007) Optimizing patient outcomes with collagenic stimulators. *J Drugs Dermatol Suppl* **6**.
- 2 Sculptra Package Insert. Bridgewater, NJ: Sanofi-Aventis.
- 3 Vleggar D, Bauer U. (2004) Facial enhancement and the European experience with Sculptra. *J Drugs Dermatol* **3**, 542–7.
- 4 Burgess C, Quiroga R. (2005) Assessment of the safety and efficacy of poly-L-lactic acid for the treatment of HIV associated facial lipoatrophy. *J Am Acad Dermatol* **52**, 233–9.
- 5 Beer K. Delayed formation of nodules from PLLA injected in the periorbital area. *Dermatol Surg* In press.
- 6 Lombardi T, Samson J, Plantier F, Husson C, Küffer R. (2004) Orofacial granulomas after injection of cosmetic fillers: histopathologic and clinical study of 11 cases. *J Oral Pathol Med* **33**, 115–20.

AUTHOR QUERIES

Dear Author

During the preparation of your manuscript for publication, the questions listed below have arisen. Please attend to these matters and return this form with your proof.

Many thanks for your assistance.

Query	Query	Remarks
1.	Au: Manufacturer details correct as added here for Scultra?	
2.	Au: Complete details for ref 5 (year, vol and page range)	