

## Cosmetic uses of botulinum toxin A

Kenneth Beer, M.D.<sup>1</sup>, Joel L. Cohen, M.D.<sup>2</sup> and Alastair Carruthers<sup>3</sup>

<sup>1</sup>Palm Beach Esthetic Center, West Palm Beach, Florida, USA

<sup>2</sup>AboutSkin Dermatology and Dermsurgery, Englewood, Colorado, USA

<sup>3</sup>Department of Dermatology, University of British Columbia, Vancouver BC, Canada

### 15.1 Introduction

The cosmetic uses of botulinum toxin (BoNT) are the most commonly used of its applications. Interest started after the effect of BoNT was shown in the treatment of blepharospasm and the first description of botulinum toxin for treatment of glabellar frown lines was in 1992<sup>1</sup>. At that time, the use of this potent neurotoxin for cosmetic indications was an interesting footnote to treatments for strabismus, torticollis and other dystonias. Subsequently, physicians began to study and use the botulinum toxins for a variety of cosmetic indications. Today, BoNT is the most commonly performed cosmetic procedure in the world. Understanding how these toxins are used in this arena is essential to any discussion of the botulinum toxins.

#### 15.1.1 Dilution of the toxin for cosmetic purposes

For the purposes of this chapter, the dilution of BoNT will be described in units of the BOTOX<sup>®</sup> brand of type A toxin. Oculoplastic specialists usually inject using a 1 ml dilution per 100 units of BOTOX<sup>®</sup>, whereas dermatologists and plastic surgeons vary in their practice towards a general range from 1 ml to 4 ml per 100 units. Variations in concentration affect the concentration gradient between the toxin and its environment. In the forehead, for instance, a dilute concentration may be preferable in order to increase migration, but, in general, clinicians use lower volumes to minimize the risk of this getting into unplanned areas. Since there is no standardized recipe for dilution and no exact way to identify precise injection sites, it is necessary to understand the principles of BoNT injections before treating patients<sup>1,2</sup>.

Although the package insert for BOTOX<sup>®</sup> recommends dilution with sterile *non-preserved* saline, studies have demonstrated that *preserved* saline provides

*Clinical Uses of Botulinum Toxins*, eds. Anthony B. Ward and Michael P. Barnes. Published by Cambridge University Press. © Cambridge University Press 2007.

## **329      Cosmetic uses of botulinum toxin A**

increased patient comfort without decreasing efficacy<sup>3</sup>. The medical literature has also reported the adding of lidocaine to the toxin<sup>4</sup>, but, although there was no significant decrease in efficacy, this practice was abandoned following a probable unrelated death. There is, in addition, a case report of adding hyaluronidase to BOTOX<sup>®</sup> in an effort enhance efficacy in the treatment of axillary hyperhidrosis<sup>5</sup>.

### **15.2    Cosmetic use of botulinum toxins**

#### **15.2.1    General tips**

Physicians should know the regional facial anatomy and understand the various interactions between the muscle groups of the face. A precise injection technique is critical when using BoNT-A, particularly when injecting the lower face, where minor variations may result in significant facial asymmetry and speech impediments. Treatment of the mid-face, lower-face and neck is best reserved for experienced injectors and for patients who have been successfully treated in the upper face.

The use of pre-treatment photography is highly recommended, as any pre-existing asymmetry that is not documented is likely to be ascribed to treatment. Written informed consent is therefore mandatory for this procedure and, included in this, patients should be notified that the use of BOTOX<sup>®</sup> in any area other than the glabella constitutes an 'off label' indication (in the USA). A proper informed consent should be specific to the areas of treatment and should mention complications, such as headache, flu-like symptoms, bruising, infection, eyelid drooping, smile asymmetry, speech enunciation changes and, although rare, dysphagia.

During the patient consultation, it is wise to explain the dose–response curve for botulinum toxin A and the estimation of the correct dose. Since each person has different anatomy, it is possible that a given individual may require more or less. In the event that more is required, a waiting period of approximately 14 days is recommended. It is important to study the patient's anatomy prior to treatment and it may be helpful to demonstrate the muscles involved through a mirror. Most experienced physicians do not routinely see patients back for post-treatment follow-up except when treating the lips, neck, blepharochalasis or hyperhidrosis, when patients are reviewed at 2–2½ weeks.

Applying ice to the injection sites before and after treatment vasoconstricts and may decrease the pain of injection and the risk of swelling, oozing and bruising. This is especially useful when treating the crow's feet and infraorbital areas. One additional method of reducing swelling is to advise patients, if medically feasible, to discontinue aspirin, vitamin E and non-steroidal

anti-inflammatory drugs at least one week prior to treatment. Some patients may benefit from topical medication such as lidocaine. When applying topical anaesthetics, it is important to identify patients with sulfa allergies. With the exception of cocaine, most topical anesthetics are vasodilators and this may reduce the efficacy of BOTOX<sup>®</sup>, thereby potentially increasing its migration to unintended areas.

Prior to any facial injection, it is important to cleanse the area of any makeup and lipstick and prepare the sites with alcohol. Makeup is a foreign substance that may contain dyes and thorough removal of this is needed to avoid any introduction into the injection sites. Be sure however, to allow the alcohol to dry completely prior to injection, as there is a theoretical concern over the alcohol inactivating the botulinum toxin.

Botulinum toxin A is commonly injected with a B-D 0.3 cm<sup>3</sup> insulin syringe with a short hub 31 g needle. The short needle minimizes the dead space of the syringe and decreases waste. Other syringes designed to minimize dead space may also be utilized. When using a syringe that has an integrated needle, fill it with enough material to inject at six sites. When using a syringe that has interchangeable needles, simply change the needle after about six injections to avoid using a blunt needle to penetrate the skin. A novice injector may wish to mark anticipated injection sites with a water-soluble pen, as this can be helpful for the planning and accuracy of injections.

Patients are instructed to 'exercise' the muscles treated after treatment for 1.5 hours and to avoid bending, lying down, going to sleep, or physically exercising for 1.5 hours to avoid the theoretical risk of diffusion.

## **15.3 BOTOX<sup>®</sup> in the glabella**

### **15.3.1 General tips for treatment of the glabella**

The glabella is currently the only FDA-approved site for cosmetic injection of BOTOX<sup>®</sup> in the USA. As such, it is the most common site for patients and physicians to begin treatment with BoNT-A. Injections of the small muscles in this area are technically simple to perform and they result in a high degree of patient satisfaction. Close attention should be paid to the eyelid and eyebrow for possible ptosis and redundant eyelid skin that, if not identified and discussed, can be a source for patient dissatisfaction following treatment. When static rhytids are present, it is important to discuss the need for adjunctive fillers, such as Restylane<sup>®</sup>, if the patient wants to eliminate all lines in this area. Stretching the skin in this area will demonstrate that, even after treatment with BoNT-A, skin creases may still be present at rest. Prior to treatment, the physician must explain

### 331 **Cosmetic uses of botulinum toxin A**

that repeated treatments, performed at 3–4 month intervals, may further reduce wrinkles in the areas treated. Patients need to be evaluated for medial recruitment from the mid-brow area. When this occurs, the contribution this makes to frown lines may be significant. Failure to discuss this and/or treat this component will result in patients thinking that BOTOX<sup>®</sup> was ineffective. In reality, some of these medial brow adductors should not be treated, as to do so might risk depression of the medial and lateral brow. Medial recruitment is caused by hyper-functional orbicularis oculi fibers just below the mid-eyebrow. Evaluation of the length and direction of the corrugators and the prominence of the procerus and nasalis muscles should also be performed prior to injection. A clear plan should be devised and discussed that addresses the individual's anatomy and concerns.

One recent study has shown that glabellar treatment may help convey positive and relaxed emotions more accurately<sup>6</sup> and that BoNT-A injections of the glabella can be beneficial for patients, who believe their faces are not communicating their emotions properly, want to delay the outward appearance of aging, or simply want to look their best.

#### **15.3.2 Glabellar anatomy**

The anatomy of the glabellar area must be understood not as a group of independent muscles but rather as a complex of inter-related muscles that must be addressed in concert. Muscles between the brows depress the medial brow. Reduction of these depressors results in a medial brow lift that is cosmetically desirable. This effect is separate and distinct from reduction of the 'scowl' lines associated with activity of these muscles. Due to the proximity of the forehead musculature, treatment of the glabella may result in diffusion to the inferior fibers of the frontalis – resulting in some degree of relaxation of lower and medial aspects of this muscle. If significant diffusion to the frontalis occurs, the medial brow lift may disappear as the brow elevators are weakened. Typically, weakening of the inferomedial frontalis results in a compensatory overactivity of the superior frontalis. This provides increased tone and a nice brow lift. This compensatory activity may be the most important mechanism in producing the brow lift recognized after glabella injection of BoNT.

Relevant brow anatomy is considered in two distinct aspects: the medial brow and lateral brow. Medial brow anatomy includes depressor supercilii, procerus, corrugator supercilii, frontalis (Figure 15.1). Lateral brow anatomy includes the lateral portion of the orbicularis oculi and the frontalis muscles (Figure 15.2) and it will be considered with the periorbital area.

The depressor supercilii originates on the nasal bridge and inserts into the skin of the mid-brow area. It draws the middle and medial portions of the brow inferiorly and medially. Corrugator supercilii also draws the mid and medial

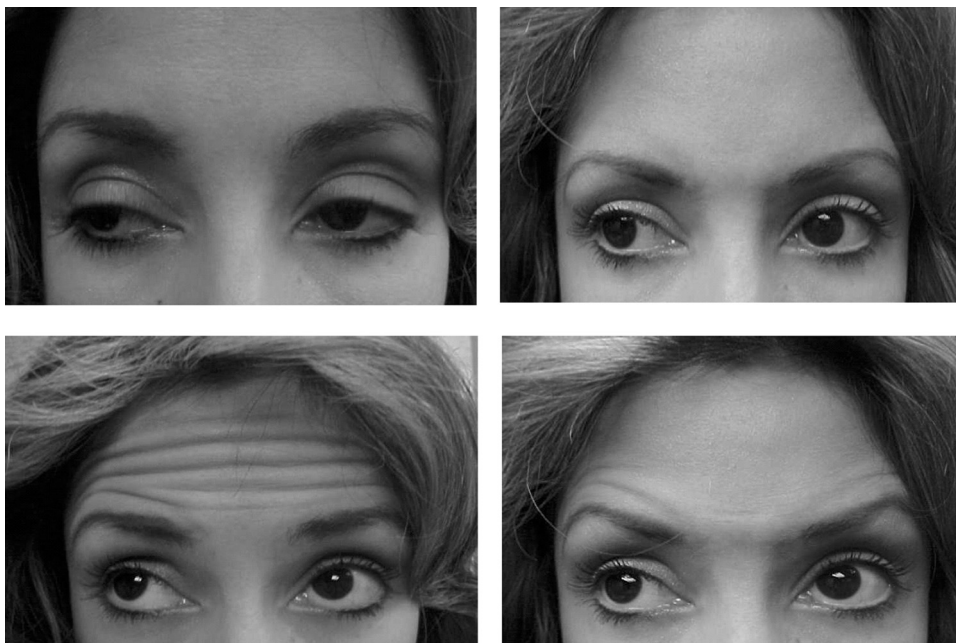


Figure 15.1 Photos on left: pre-treatment, a 36-year-old woman, arched brow, mid-frontalis musculature most prominent, and muscular lines do not extend all the way up to the hairline. Photos on right: 12 days after 18 U BOTOX<sup>®</sup> using five injection sites, –4 units midline, 4 units about 2 cm lateral to midline (all three being about 4 cm above brow) and –3 units injected laterally on each side (about 1.5 cm higher than medial injection points, and about 1.5 cm medial to temporal fusion line). Note the preservation of the arched brow at repose and the inferior frontalis musculature, which remains after treatment – allowing maintenance of brow shape and position as well as expression. Photos: Joel L. Cohen, MD.

brow in these directions. It originates on the nasal bone and inserts into the skin of the brow above the pupil. Variations in anatomy mean that the insertion point into the brow may be more lateral in some people than in others. This variation is occasionally responsible for movement of the brow even after the glabella has been correctly injected. In addition to these two muscles, the third muscle that forms the medial brow complex is the procerus. Unlike the other two muscles, which tend to form vertical lines by drawing the skin medially, the procerus tends to form horizontal lines by drawing the skin inferiorly. As these muscles contract they form etched-in lines perpendicular to the direction of their action. The procerus muscle originates on the nasal bridge and inserts into the skin of the mid-glabella directly above it. Treatment of this area with botulinum toxins typically addresses the muscles in concert. Opposing these depressors is the frontalis muscle, which is a brow elevator and may be a solitary wispy sheet that invests the entire forehead or it may be two muscles separated by a thin fascial component in the mid-forehead.

### 333 Cosmetic uses of botulinum toxin A

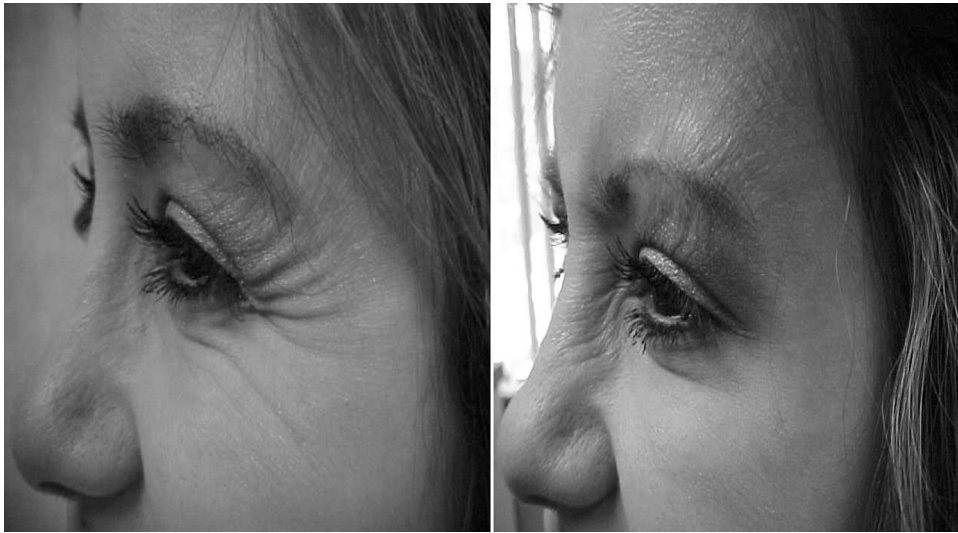

Figure 15.2 Crow's feet photos: 9 U BOTOX® into the crow's feet – four at superior aspect, two mid, two lower and one lateral lower lid. Photos: Joel L. Cohen, MD.

#### 15.3.3 Injection technique for the glabella

Variations in technique exist between expert injectors in the approach to the medial brow complex. Many injectors will inject using 20–30 U in five injection sites<sup>7</sup>. Other injectors will inject this site with three injections, allowing diffusion to treat the adjacent areas. Differences in muscle mass affect the amount of toxin needed for relaxation of the muscles. Patients with hypertrophic muscles in this area require higher doses of toxin and men will require more material than women<sup>8</sup>.

The most frequent sites of injection are the following: upper procerus (one injection), medial corrugator (one on each side) and lateral corrugator muscles (one injection on each side). The lateral corrugator injection is placed at least 1 cm above the orbital rim, in order to avoid diffusion to the adjacent orbital septum. Diffusion to the levator palpebrae superioris muscle may cause ptosis.

Adjustments may be made for prominent medial recruitment require 2–3 U about 1.5 cm above the bony supraorbital rim and for prominent procerus activity (5–7 U). The supraorbital rim is a reliable landmark and it, rather than the eyebrow, should be used to identify locations for injections. Avoid forceful injections in this area as this may increase the risk of diffusion as well as increase the risk of bruising and headaches. During the injection, patients are asked to frown, so that the length and direction of the corrugator can be followed.

### **15.3.4 Complications from glabella injections**

Complications from injections of toxins to the brow area are rare. The most common complications include headache, respiratory infection, a flu-like syndrome, temporary eyelid droop and nausea<sup>9,10</sup>. Others include bruising or temporary periorbital oedema (the incidence of which increases with increased volumes of injection). When evaluating the actual incidence of complications, it is worth noting that for BOTOX<sup>®</sup>, many of the complications listed in the package insert were comparable to reactions seen with placebo. The management of complications is critical to patient safety and satisfaction. Most complications resolve spontaneously and require only patient reassurance.

Ptosis is the most unsettling complication seen with treatment of the glabellar complex and its management is subject to debate. Oculoplastic surgeons recommend treatment of ptosis with over-the-counter Naphcon A or apraclonidine hydrochloride (IOPIDINE<sup>®</sup> 0.5% Ophthalmic Solution), an alpha adrenergic agonist. Beware however, that Iopidine may unmask an underlying glaucoma, so this should be reserved for refractory cases. Untreated, the ptosis will resolve over the span of a few weeks.

## **15.4 Prominent forehead lines**

### **15.4.1 General tips**

Prior to treatment, it is crucial to note the brow position, shape, degree of blepharochalasis/dermatochalasis or scars using photographs, as post treatment asymmetry or eyelid redundancy is much more easily explained with pre-existing photos.

Women tend to have an arched brow whereas men tend to have a more horizontal brow orientation. A female arched-brow may be preserved by avoiding treatment of the lateral brow elevators and a weakening of the lateral brow depressors. Since the lower 3 cm of frontalis elevates and shapes the brow, the lateral 1/3 of this zone should be avoided in women to avoid brow heaviness.

### **15.4.2 Anatomy of the forehead musculature**

The frontalis muscle normally varies significantly. The vertical orientation of the frontalis muscle fibers allows it to function as a brow elevator. Knowledge of its interaction with musculature of the medial brow and lateral brow allows the skilled physician to tailor his or her technique to fit the goals and anatomy of each patient. To activate the frontalis muscle, have the patient elevate their brows.

The frontalis muscle is continuous with the galea aponeurotica in its superior aspect. Inferiorly, it invests the skin of the brow. Contraction of this muscle

### 335 **Cosmetic uses of botulinum toxin A**

not only raises the brow but also creates transverse rhytids across the forehead. The lateral border of the frontalis muscle is the temporal fusion plane. This plane is the boundary between the frontal and temporal bones and is easily palpated in most people. Inferior and slightly lateral to the temporal fusion line, the downward pull from the orbicularis muscle counteracts the upward pull of the frontalis. Understanding the interaction between these two muscles is critical when creating a brow lift using botulinum toxins (Figure 15.3).

#### 15.4.3 **Injection technique: forehead**

Injecting the frontalis muscle takes account of the anatomy and goals of the individual being treated. Some patients desire to be wrinkle free. However this should be avoided, as eliminating every wrinkle of the forehead can increase the length of the forehead and neutralize the elevation needed by the brow to avoid sagging. In order to preserve the lateral brow lift in a woman, a different injection technique is required to that for a horizontal brow for a man. In a woman, injecting near the temporal fusion plane should be avoided, allowing the lateral brow to lift. In a man, one may inject a small amount of BOTOX® in the lateral aspect of the forehead to produce a horizontal brow. In addition, injection of the depressor component of the orbicularis should not be performed in a man, as it will accentuate the brow lift by reducing the depressor action on the lateral brow. When injecting the brow, it is best to avoid the most inferior rhytid in older

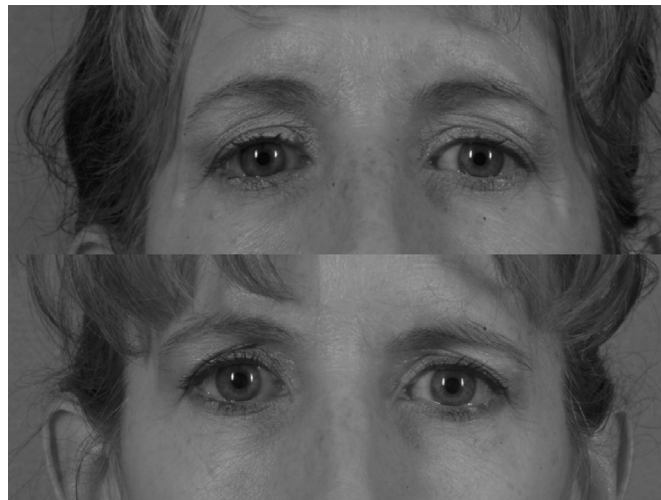


Figure 15.3 Lateral brow lift. Bottom: Pre-injection, note the upper eyelid redundancy ('hooding') present just below the lateral brow. Top: Post-injection of 5 U BOTOX® at a single point (described above) at the lateral and inferior aspect of the lateral brow on each side. Photos: Joel L. Cohen, MD.

women, as this musculature elevates the brow. Removing this results in a 'heavy' brow that will need to be manually suspended for makeup to be applied. Finally, for all forehead treatments, inject superficially, causing a bleb, rather than injecting at the depth of the periosteum. Gently massage each of the blebs for a few seconds after the treatment to facilitate some mild diffusion to these large muscles.

When injecting a woman with minimal skin laxity, several injections are made into the frontalis in a row that uses between five and nine injections. Consideration must be given to particularly wide or tall foreheads as well as to preferred hairstyles. Patients with tall foreheads will benefit from a second row of injections superior to the first one. Wider foreheads require more injections to cover the expanse. Failure to extend the injections laterally will result in a 'Mr. Spock' brow, caused by untreated lateral frontalis musculature.

As one injects the horizontal lines, one should inject higher moving laterally. In most patients, one should remain about 1.5 cm medial to temporal fusion line. Medial injection points should be at least 3–3.5 cm above the brow. A 1 or 2 cm dilution is appropriate and this dilution will reduce the chance of spread to unintended muscles. Doses vary depending on size of forehead and muscle mass. Treatment of the glabella can be accomplished at the same visit as the frontalis treatment. Alternatively, injectors can first treat the glabella and have patients follow-up 2 weeks later – which may potentially allow lower dosages to then be used in the forehead as there will be some degree of spread to the frontalis after the glabellar treatment. Pre-treatment marking during animation will avoid injecting too inferiorly. Average doses for frontalis treatment in women typically range from 10 to 30 units, whereas a man may require 20–40 units. One study has shown that higher dosages in the forehead are clearly associated with a longer duration of efficacy in this area<sup>10</sup>.

Inactivation of the medial frontalis causes a compensatory elevation resulting in a rise of the lateral brow. This may be augmented when combined with an injection of the depressor aspect of the orbicularis. When treating men, injections of the brow should be more horizontal in men and should extend to the lateral aspect of the brow (in contrast to injections of female brow where injections tend to become more superior as the lateral brow is treated). **Men recruit more laterally than most women and are more likely to require an injection of BoNT vertically above the lateral canthus at the orbital rim.**

Au: Please check if "Men" should be replaced by "Males" as per the change in the word document.

#### 15.4.4 Complications: forehead

Complications that arise from injecting the frontalis include haematoma, brow drooping and headache. One problem that is encountered is the 'Mr. Spock' brow that results when the lateral aspects of the frontalis elevate the lateral

## **337      Cosmetic uses of botulinum toxin A**

brow producing a quizzical look. This situation is easily rectified with about 2 units in the lateral temporalis. Another situation unique to frontalis injections is an electrical shock sensation that occurs when the supraorbital nerve is hit by the needle. Patients report a sharp pain that radiates along the distribution of this nerve on frontal scalp. This situation is easily solved by avoiding injections in the mid-pupillary line or avoiding injecting too deeply.

### **15.5    Crow's feet and infraorbital rhytids**

#### **15.5.1    Anatomy of the periorbital area and of the eyelids**

Variations of the lateral crow's feet exist among patients<sup>11</sup>. The major muscle affecting the orbital area is the orbicularis oculi, which is a thin band surrounding the eye. Its action is to constrict the skin surrounding the eye. Since it is a circular muscle, its action is different in different areas. For example, inferior to the lateral brow it works as a brow depressor. Its portion superior and lateral to the pupil may potentiate frowning and, at times, be responsible for patients that are able to frown after adequate injection of the glabella complex. The pretarsal component of this muscle has important actions for maintaining the shape of the periorbital areas. Without the actions of the orbicularis, there is a risk of festooning<sup>12</sup>.

#### **15.5.2    Injection technique for the periorbital areas**

The single most popular injection of the orbicularis muscle is to prevent and treat the lateral canthal rhytids commonly known as crow's feet. Treatment for these wrinkles has high patient satisfaction and is technically simple. Using between 10–12 units of BOTOX<sup>®</sup> on each side, three or four injections are made<sup>13</sup>. The injections should be made at least 1 cm lateral to the orbital rim to avoid any unintended treatment of the ophthalmic muscles (which would produce diplopia). Since the muscles are very superficial, injections may be made by raising a wheal. At the inferior aspect of the treatment zone, care must be taken not to treat every last wrinkle as this will treat the zygomaticus minor and major, impairing the ability to raise the corners of the mouth and lips.

One of the most interesting and technically challenging aspects of injecting the periorbital area is the brow lift for women seeking this treatment. Performing this injection involves injecting approximately 3–6 units of BOTOX<sup>®</sup> into the portion of the orbicularis that tugs the lateral brow down<sup>14</sup>. When done in conjunction with injection of the medial frontalis, significant lateral brow elevation may be achieved. In severe cases of eyelid redundancy, surgical blepharoplasty is the treatment of choice.

The lower eyelid may be treated using 2 units of BOTOX<sup>®</sup> placed subdermally in the mid-pupillary line approximately 3–4 mm below the lid margin<sup>15</sup>. When this injection was administered in conjunction with treatment of crow's feet, the results were an improvement of infraorbital rhytids and a widening of the palpebral aperture, especially on smiling. This treatment should be reserved for those patients with minimal lower eyelid laxity.

### **15.5.3 Complications from injection of the orbital area**

The most common complication from injections in this area is small hematomas and bruises due to the rich vasculature of this area. More serious complications include ptosis which occurs from injections that affect the levator palpebrae superioris. Injections placed too inferiorly on the zygomatic arch may lead to inability to raise the corners of the mouth or raise the lips and this can be most unsettling for both physician and patient alike. Diplopia may occur from either direct injection or diffusion that brings toxin in contact with the extraocular musculature. Photophobia has also been reported.

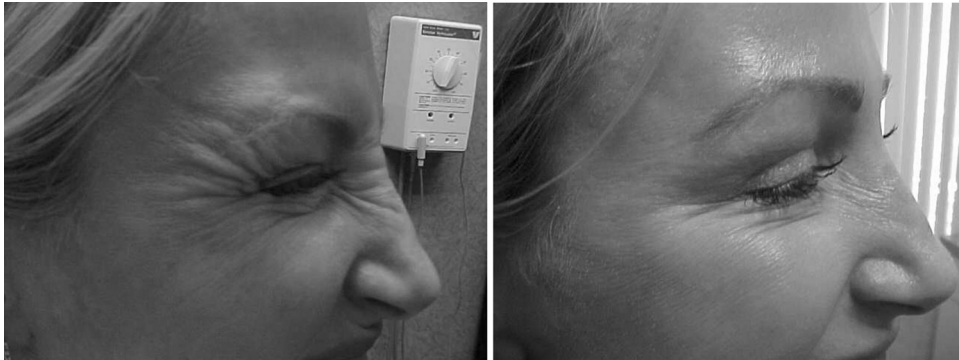### **15.5.4 BOTOX<sup>®</sup> for lateral brow lift**

Elevation of the lateral brow tends to give the patient a more alert, open-eyed look – one of the hallmarks of a youthful brow. Precise injections of BoNT-A into the superior and lateral aspect of orbicularis oculi can impart an arch to many brows. Specific injection sites are essential to locate and require some patient participation to elicit the correct musculature on each side. The first step in this procedure is to ask the patient to elevate their brow and find the temporal fusion plane (where the lateral frontalis ends). Then ask the patient to close their eyes forcefully and mark the site that the orbicularis oculi maximally pulls the lateral brow inward and downward. Inject 4–6 units just inferior to the point of maximal pull – making sure this point is at least 1.5 cm away (lateral-inferior) from temporal fusion area elicited in step one<sup>14</sup>. This technique can achieve a 2–3 mm elevation of lateral brow. Fillers such as Restylane<sup>®</sup> may be injected into the lateral aspect of the brow to alleviate upper lid redundancy. Combination therapy with BoNT-A and filler may increase the duration of response, as has been documented in other areas of combination therapy such as the glabella.

### **15.5.5 'Bunny lines'**

The upper nasalis muscle is responsible for the formation of 'bunny lines' at the bridge of the nose that extend horizontally toward the medial canthus. These lines may form a sharp contrast to a perfectly smooth glabellar area, and may be seen as a sign of someone who has had glabellar and crow's feet

## 339 Cosmetic uses of botulinum toxin A



Au: Please provide citation for figure 15.4.

**Figure 15.4** A 40-year-old woman with prominent bunny lines treated with 4 U BOTOX<sup>®</sup> to each lateral nasal side wall (in addition, patient was treated in the crow's feet with 12 units to each lateral aspect of the orbicularis oculi). Photos: Joel L. Cohen, MD.

treated with botulinum toxin A. It is recommended that the nasalis be injected in concert with the glabella. This muscle can be isolated for injection by having the patient frown, smile, or squint. The nasalis muscle is injected with approximately 3–5 units of botulinum toxin A superficially at each medial proximal sidewall of the bridge of the nose. Insertion of the needle must be gentle and should be in the subcutaneous but not periosteal plane. Caution must be exercised when injecting this area as an injection that is placed lateral to the nasal sulcus may affect the levator labii superioris aequae nasi, resulting in a drooping of the lateral lip. To complete this cosmetic unit, it is best to also treat the procerus with 5–7 units as well to complement the glabella and nasalis regions<sup>16</sup>.

### 15.6 Lower face

Treatment of the lower face requires more advanced knowledge of injection techniques as well as of the relevant anatomy. When considering the anatomy of the lower- and mid-face, it is helpful to think about how injections will affect the position of the mouth and how they will affect the contour of the lips. It is also important to consider treatment of these areas in conjunction with soft tissue augmentation.

#### 15.6.1 General anatomy of the lower face

The corners of the mouth are moved by two sets of opposing muscles: elevators and depressors (Figure 15.5). The major elevator of the lateral mouth and cheek is the zygomaticus major. Medial elevation is accomplished by the zygomaticus minor as well as the levator labii superioris and minor.

The orbicularis oris is a sphincter-like muscle surrounding the mouth. It is responsible for pursing the lips resulting in perioral rhytids. Women frequently

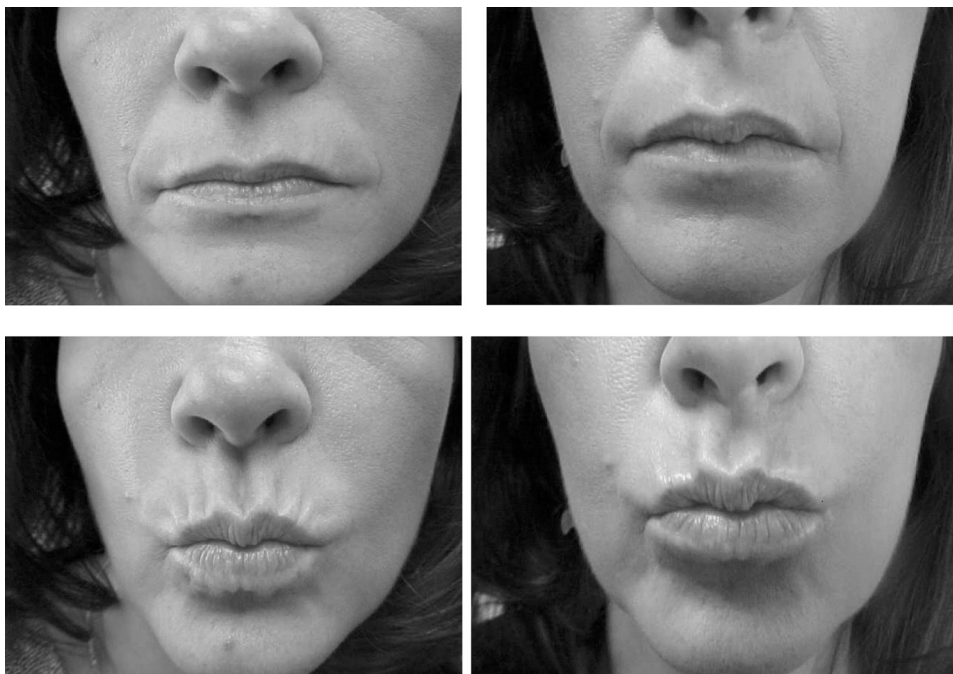

Figure 15.5 Photos on left: pre-treatment, 42-year-old woman, moderate perioral lines with pursing lips, no significant baseline imprinted superficial lines at repose. Photos on right: 14 days post-treatment with 8 U BOTOX<sup>®</sup> (10 injection sites, as diagrammed below). Note: post-treatment lips appear fuller, especially with movement – likely a pseudo-augmentation appearance due to upward pull of the remaining superior aspect of the orbicularis oris from the levator labii superioris aleque nasi and zygomaticus insertions. In addition, there is preservation of Cupid's bow symmetry as midline philtrum is maintained. Photos: Joel L. Cohen, MD.

complain that lipstick 'bleeds' into these lines and any improvement is greatly welcomed by patients.

The position of the lips is also controlled by depressors that counteract the elevator muscles. The depressor anguli oris will, over time, cause the lateral aspects of the mouth and lips to turn inferiorly. This imparts a negative impression and is a frequent impetus for patients seeking cosmetic improvement. The explosion of filler substances available to use in conjunction with the toxins has greatly enhanced our ability to treat these marionette lines.

The mentalis muscle lies at the most inferior portion of the face. It originates in the incisive fossa and inserts into the skin of the chin and is responsible for the appearance of lines in the chin area that are variously described as 'pebble chin' or the more dreaded 'scrotal chin.' Treatment of this muscle relaxes the mentalis and leads to significant improvement of the appearance of the chin.

## 341      **Cosmetic uses of botulinum toxin A**

### **15.6.2 Lips**

#### **General tips for lips**

The lips are a popular site for BoNT-A treatment in women. Patients seeking correction of lip rhytids typically have many questions from the common misconception that botulinum toxin A should not be used in the lower face. Treatment with botulinum toxin A not only softens vertical lip lines, but also provides the appearance of fuller lips. This results from diminishing the hollowing appearance within the vertical muscular bands, offering a 'pseudo-augmentation.' Smokers tend to have more dramatic results than non-smokers. Patients with deep perioral rhytids should combine botulinum toxin A with fillers, such as collagen or hyaluronic acid. CO<sub>2</sub> resurfacing is still a viable alternative for patients with significant lines and botulinum toxin A will enhance and prolong the efficacy of this procedure. During the consultation, it is important to explain that BoNT-A will soften, but not completely prevent or obliterate vertical lip lines. It should also be clearly explained and stated on consent forms that injecting lip lines may decrease the ability to purse lips. This action is used for kissing or putting on lipstick, whistling, drinking from a straw, and creating a seal around a spoon. Knowing this, one should avoid treating patients who play a wind instrument or plan on scuba diving or snorkeling in the next few months. In addition, such pursing of the lips is required to some extent for enunciating words with 'p,' 'b,' and sometimes 'j and g.' You can illustrate this for patients by having them say 'peanut butter and jelly.' Patients in professions that require perfect phonation may not be good candidates for this treatment area.

The effect of treatment usually lasts several weeks less than in other regions, averaging about 7–10 weeks duration of treatment in our experience<sup>17</sup>. In addition, because the dosages used are so small, these patients are followed up 2 weeks after treatment to evaluate efficacy by comparing current photos to pre-treatment photos, and touching-up if occasionally necessary. Treatment should involve the upper and lower lip. In our experience, some of the patients who just wanted upper lip treatment vaguely expressed that it 'felt funny' until the lower lip was treated as well.

#### **Injection technique for lips**

Treatment of the lips usually hurts more than other sites. Thus, these patients should ice the perioral area prior to the injection. Our usual 1 cm<sup>3</sup> dilution for other sites is diluted by a factor of 5:1 for the lips. The dose for this area being only 6–9 units and we use the dilution to obtain a more even relaxation.

In the upper lip, two injection points are used. They are along the vermilion border on each side of the upper lip spaced about 1.5 cm apart, as well as

another more superior injection site between them 1 cm above the vermilion border. Maintenance of symmetry is very important to ensure preservation of the philtrum midline. For the lower lip, we inject only along the vermilion border – using two sites on each side of the lip, also spaced about 1.5 cm apart. Like the forehead, we press down on the injection sites for a few seconds after the treatment to facilitate some mild diffusion.

### **15.6.3 ‘Gummy smile’**

The ‘gummy smile’ refers to excessive showing of the gums above their maxillary teeth (probably responsible for the expression of ‘being long in the tooth’). This can be treated by targeting the levator labii superioris aequae nasi muscle. This muscle may be identified by asking the patient to move the tip of his or her nose<sup>18</sup>. Injection of between 1–3 units of BOTOX<sup>®</sup> at each superior medial nasolabial fold will relax this muscle. Without the elevation provided by this muscle the upper lip will be lowered enough to cover the upper portion of the teeth while the patient is smiling. Improvement of this area may be enhanced with a filler substance used adjunctively to diminish prominent superior nasolabial folds. This treatment is best for younger patients with significant upper gum show when smiling, sometimes called the ‘extreme canine smile.’ Caution should be exercised when treating older patients as treatment can cause an accentuation of mid-face flattening and cutaneous upper lip vertical elongation, which normally occurs with aging, and may be undesirable in those patients. Treatment of the levator labii superioris aequae nasi should be reserved for those physicians with a great deal of experience injecting botulinum toxin A in the lower aspect of the face. Complications seen in this area may include asymmetry of the lips and depression of the corners of the mouth.

### **15.6.4 ‘Downturned smile’**

The ‘downturned smile’ can misrepresent emotions, imparting a sad or concerned appearance. This may be corrected with botulinum toxin injections of the depressor anguli oris (DAO) muscle. This muscle can be identified for injection by palpating along the jawline as the patient frowns or pulls down the corners of the mouth. The average doses of BOTOX<sup>®</sup> is between 3–5 units per side. Injections are made into the posterior-aspect of DAO. This permits the zygomaticus muscle to act unopposed and elevate the corners of the mouth to a horizontal, more aesthetically pleasing position. Great care should be exercised in treating this area as a medial injection can diffuse to the depressor labii inferioris causing slurred speech. This area should be avoided in patients who play wind instruments, sing or are broadcast journalists or scuba divers.

### 343 **Cosmetic uses of botulinum toxin A**

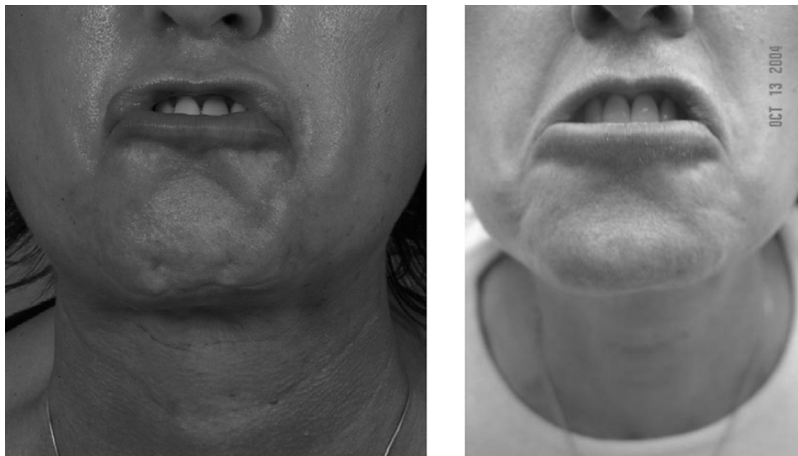Perhaps more than any other, this area is typically treated in conjunction with a filler such as Restylane®.

#### **15.6.5 Mentalis-‘golf ball chin’**

Excessive wrinkling of the chin is produced by the mentalis muscle, which originates on the canine fossa and inserts into the dermis of the chin. This pebbly appearance is made more prominent when speaking or chewing. Injections of this area with BoNT-A will alleviate these rhytids and impart a more youthful appearance to the lower face. The mentalis muscle may be triggered by asking the patient to push his or her lower lip downwards. Injections of the area may be made with 4–8 units BOTOX® injected at the bony part of the chin (either as a single midline injection or as two injections approximately 1 cm apart). This treatment can also be used to soften mental crease. Be cautious however, as too lateral an injection can diffuse to depressor labii inferioris, resulting in slurred speech. Just above this area of musculature lies the mental crease. Treatment of a prominent mental crease can be enhanced with fillers.

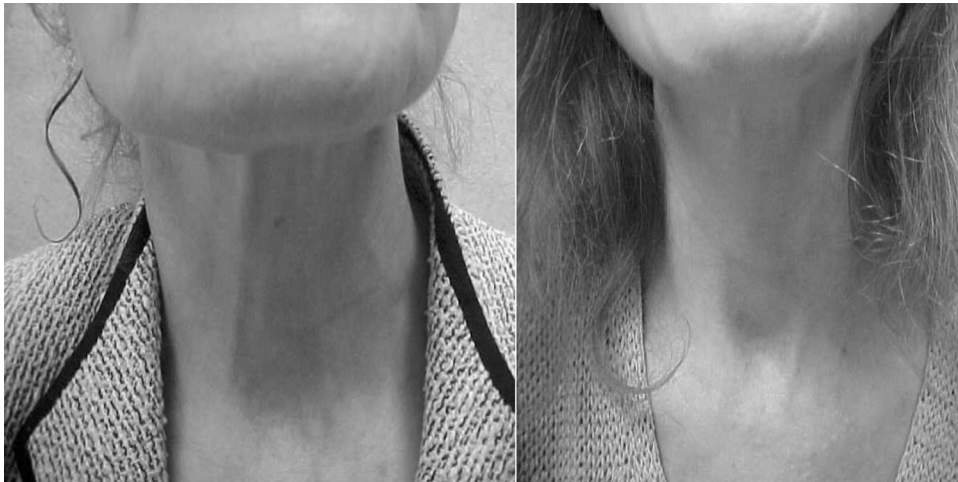#### **15.6.6 ‘Vertical neck bands’ and ‘horizontal necklace lines’**

After weight loss, chin/neck liposuction or general ageing changes, some patients complain of prominent vertical bands in their neck. These hyperfunctional platysmal bands differ from horizontal lines, which are believed to be from prominent SMAS. The platysmal bands can be relaxed by experienced botulinum toxin A injectors. The specific injection sites are determined at rest, and



**Figure 15.6** A 52-year-old woman who complained of dimpling in her chin when speaking and chewing gum. She was treated with two three-unit injections of BOTOX® into the mentalis (in addition, her horizontal neck bands were treated the same day with a total of 10 U BOTOX®). Photos: Joel L. Cohen, MD.

Au: Please provide citation for figure 15.6.



**Figure 15.7** A 56-year-old woman was treated with a total of 18 U BOTOX® for vertical neck bands present at rest. The right band was treated with 12 U and the left band 6 U. Photos: Joel L. Cohen, MD.

Au: Please provide citation for figure 15.7.

without animation. Typically 20–35 units total are used, with re-treatment 2–3 weeks later for undercorrection. Injections of between 1–3 units are spaced approximately 1.5 cm apart along the band or horizontal line. Grasp the band between thumb and forefinger and ensure that each injection is superficially placed. Deeper or larger injections may possibly relax the platysma enough to allow the elevators of the lower face to more effectively lift the neck and jowls. However, one report of severe dysphagia occurred following injection with 60 units<sup>17</sup>. This patient required a nasogastric tube feeding for 6 weeks and caution should be exercised when treating the neck. If a patient complains of swallowing difficulties following a procedure they should be evaluated immediately. Treatment should consist of soft foods, metoclopramide to stimulate upper GI motility and ENT evaluation. This procedure is best for our young patients with good skin tone, post-submental liposuction, or post-face/necklift.

### 15.6.7 Newer indications for treatment with botulinum toxins

#### Radish calf

Hypertrophic gastrocnemius muscles are the cause of psychological stress for women affected by enlarged muscles of the calf area. BoNT-A has been used to reduce the girth and improve the contour of the calves of oriental women. One study treated so called ‘radish calves’ with botulinum toxin type A. (Ref. PRS OCT. 2003) Doses ranging from 32, 48 and 72 units were injected into the medial head of the gastrocnemius muscle. The results from this study demonstrated an improvement of leg contour with a ‘slight’ decrease in girth.

## 345 **Cosmetic uses of botulinum toxin A**

There was no apparent detriment to any functional component of the muscle group and the improvement lasted for about 6 months. Not surprisingly, the authors noted that there was a low patient satisfaction with this procedure as there was apparently little change rendered by the treatment. Injections of radish calves will most likely be limited to very select patients who are greatly distressed by the contour and size of their calves.

### 15.6.8 **Adjunctive uses of botulinum toxins**

One of the most interesting aspects of botulinum toxins is their use in conjunction with other minimally invasive procedures such as injection of soft tissue augmentation products and with lasers and other light sources. Combinations of these procedures is virtually unlimited.

#### **The use of toxins with fillers**

The combination of fillers with botulinum toxins makes sense, as many patients desiring treatment of dynamic rhytids also need volume replacement. From a mechanistic perspective, the use of toxins makes eminent sense, as they will tend to reduce the ability of muscles to pump fillers out of their sites of injections. Among the fillers that are used with botulinum toxins include collagen, calcium hydroxylapatite (Radiesse<sup>®</sup>), hyaluronic acids and poly-L-lactic acid (Sculptra<sup>®</sup>). Permanent fillers that may be used with toxins include silicone and Artefill<sup>®</sup>.

Many of the dynamic rhytids treated with botulinum toxins will have some static component at the time of treatment. Despite adequate inhibition of muscle activity, these resting wrinkles persist. Fillers offer an additional opportunity to correct the static rhytid. Areas amenable to correction with non-permanent fillers and toxins include the glabella, periorbital area, mentalis, perioral area and in limited cases, the nasolabial creases.

Materials used in conjunction with BoNT in the glabella include collagens and hyaluronic acids. Although calcium hydroxylapatite may be used, caution should be exercised when injected near the trochlear plexus of vessels. Collagens that may be used for glabella treatment include those that are non-crosslinked (e.g. Zyderm<sup>®</sup> I and II and Cosmoderm<sup>®</sup> I and II). Isolagen<sup>®</sup> will most likely also be an acceptable filler for this area. The crosslinked collagens are not recommended for this area.

Useful hyaluronic acid products in this area in concentrations between 5.5 mg ml<sup>-1</sup> and 20 mg ml<sup>-1</sup> include those that are animal derived as well as those that are non-animal derived. Large particle size is best avoided for a filler for the glabella.

More durable fillers such as Radiesse<sup>®</sup> may be used in the glabella in conjunction with botulinum injections. Paralysis afforded by the toxin will

allow the scaffolding of the calcium hydroxyapatite to remain relatively immobile and may help to improve the ingrowth of fibroblasts and collagen. The major caveat with using this product in this area is that injection of thick products has resulted in intravascular injection of material with resulting necrosis of the skin. In addition, the vascular plexus for the eye may be the unintended recipient of filler via retrograde flow.

The same caution exercised when injecting the glabella when not using toxins must also be used when providing combination therapy. Fillers such as silicone and Artefill® should be used only by experienced injectors. Poly-L-lactic acid should also be used by experienced injectors in this area.

When treating the glabella with a filler and botulinum toxin, it is recommended that the filler be injected prior to the injection of the toxin. This will reduce the risk of untoward migration and unintended paralysis of levator muscles.

The periorbital area may also benefit from use of toxins with fillers. As with the glabellar area, fillers will help to alleviate the static component of the rhytid while the BOTOX® will prolong the duration of the soft tissue correction by decreasing the muscular pumping action.

Collagens have long been used to fill the periorbital areas. The thin skin of the area mandates that one of the thinner collagens is used (such as Cosmoderm® or Zyderm®). Using one of the crosslinked products is not recommended for this area. Hyaluronic acids are also helpful for adjunctive treatment of this area and products intended for superficial or mid-dermal placement (but not deep dermal or sub-cutaneous placement) are tolerated well in these areas. As with any periorbital injection, care should be taken to avoid intravascular injection.

Rhytids of the upper lip are one of the best places to use combinations of fillers and toxins. Patients that have static and dynamic perioral rhytids will greatly benefit from the synergistic effect of the two treatments. Fillers that are effective when used with botulinum toxins include collagens (the type depends on the thickness of the wrinkle and of the skin) and the hyaluronic acids (particularly ones with small particle size). Care should be exercised when using Sculptra® in this area as it may result in subcutaneous papule formation. Silicone may be useful as long as a micro-droplet technique is used and enough toxin is given to minimize the risk of silicone migration during the encapsulation process. There is not enough data to know whether Radiesse® may be used for this area, but, if one uses toxin and allows the product to remain immobile, it might be an acceptable long-term alternative.

Injection of the depressor anguli oris in conjunction with volume replacement of the marionette lines is another combination that is synergistic. The toxin not only helps to reduce the depressor function (allowing for less filler to restore

## 347 **Cosmetic uses of botulinum toxin A**

proper positioning of the corner of the mouth) but will also decrease the muscular pumping that tends to move fillers out of their intended locations.

Fillers used for the marionette lines include collagens, hyaluronic acids, poly-L-lactic acid, silicone and calcium hydroxylapatite. As with other locations, each has its relative risks and benefits for this location.

Mentalis creases are also ideally treated with combinations of fillers and toxins. The use of typical amounts of toxin in this area will relax most of the dynamic rhytids associated with muscle actions here. Depending on the degree of static rhytids, fillers can often make the difference between a patient that is not satisfied and one that is thrilled. As with the marionette lines, the choice of filler for this area depends on the experience and preference of the physician and patient.

Adjunctive use of fillers for neck treatment is an area that will most likely receive attention in the future. One filler that seems to enhance the performance of the botulinum toxins is poly-L-lactic acid, which adds volume to this area. Hyaluronic acids, collagens, calcium hydroxyapatite and silicone are helpful for treating this area but require large volumes.

## **15.7 Conclusions**

Botulinum toxins are frequently used for cosmetic indications. Areas once thought not to be amenable to treatment are now routinely treated. Newer uses of these drugs in conjunction with other cosmetic procedures have enhanced the utility not only of the toxins, but also of these adjunctive treatments. What an exciting time to be in cosmetic dermatology!

## **REFERENCES**

1. Carruthers, J.D. and Carruthers, J.A. (1992). Treatment of glabellar frown lines with *Clostridium botulinum-A* exotoxin. *Journal of Dermatologic Surgery and Oncology*, **18**(1), 17–21.
2. Hsu, T.S., Dover, J.S. and Arndt, K.A. (2004). Effect of volume and concentration on the diffusion of botulinum exotoxin A. *Archives of Dermatology*, **140**(11), 1351–4.
3. Dover, J.S. and Arndt, K.A. (2002). Pain associated with injection of botulinum A exotoxin reconstituted using isotonic sodium chloride with and without preservative: a double-blind, randomized controlled trial. *Arch. Dermatol.*, **138**(4), 510–14.
4. Lewis, C. (2002). BOTOX cosmetic: a look at looking good. *FDA Consumer*, **36**(4), 11–13.
5. Goodman, G. (2003). Diffusion and short-term efficacy of botulinum toxin A after the addition of hyaluronidase and its possible application for the treatment of axillary hyperhidrosis dermatologic surgery. *Dermatologic Surgery*, **29**(5), 533–8.

6. Finn, C., Cox, S. E. and Earl, F. (2003). Social implications of hyperfunctional facial lines. *Dermatol. Surg.*, **29**, 450–5.
7. Carruthers, A., Carruthers, J. and Said, S. (2005). Dose-ranging study of botulinum toxin type A in the treatment of glabellar rhytids in females. *Dermatologic Surgery*, **31**(04), 414–22.
8. Carruthers, A. and Carruthers, J. (2005). Prospective, double-blind, randomized, parallel-group, dose-ranging study of botulinum toxin type A in men with glabellar rhytids. *Dermatologic Surgery*, **31**(10), 1297–303.
9. Carruthers, J. A., Lowe, N. J., Menter, M. A., Gibson, J., Nordquist, M., Mordaunt, J., Walker, P. and Eadie, N. (2002). A multicenter, double-blind, randomized, placebo-controlled study of the efficacy and safety of botulinum toxin type A in the treatment of glabellar lines. *Journal of American Academy of Dermatology*, **46**, 840–9.
10. Carruthers, A., Carruthers, J. and Cohen, J. (2003). A prospective, double-blind, randomized, parallel group, dose-ranging study of BOTOX<sup>®</sup> in female subjects with horizontal forehead rhytids. *Dermatologic Surgery*, **29**, 462–7.
11. Kane, M. A. (2003). Classification of crow's feet patterns among caucasian women: the key to individualizing treatment. *Plastic and Reconstructive Surgery*, **112**(Suppl. 5), S33–S39.
12. Goldman, M. (2003). Festoon formation after infraorbital botulinum-A toxin: a case report. *Dermatologic Surgery*, **29**(5), 560.
13. Lowe, N. *et al.* (2005). Double-blind, randomized, placebo-controlled, dose-response study of the safety and efficacy of botulinum toxin type A in subjects with crow's feet. *Dermatologic Surgery*, **31**(3), 257–62.
14. Cohen, J. and Dayan, S. (2005). Botulinum toxin type A in the treatment of dermatochalasis: a prospective study evaluating temporal brow elevation. *American Academy of Dermatology*, **52**(Suppl. 3), 86.
15. Flynn, T., Carruthers, J. A., Carruthers, A. and Clark, R. (2003). Botulinum A toxin (BOTOX<sup>®</sup>) in the lower eyelid: dose-finding study. *Dermatol. Surg.*, **29**(9), 943–50.
16. Tamura, B., Odo, M., Chang, B., Cuce, L. and Flynn, T. (2005). Treatment of nasal wrinkles with botulinum toxin. *Dermatologic Surgery*, **31**(03), 271–5.
17. Carruthers, J. and Carruthers, A. (1999). Practical cosmetic BOTOX<sup>®</sup> techniques. *Journal of Cutaneous Medicine and Surgery*, **3**(Suppl. 4), S49–52.
18. Pessa, J. E. (1992). Improving the acute nasolabial angle and medial nasolabial fold by levator alae muscle resection. *Annals of Plastic Surgery*, **29**(1), 23–30.